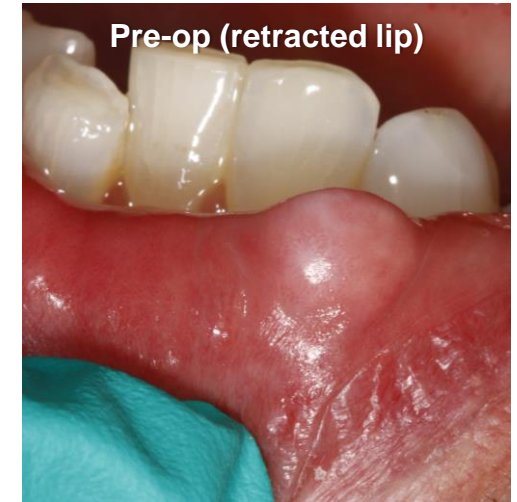
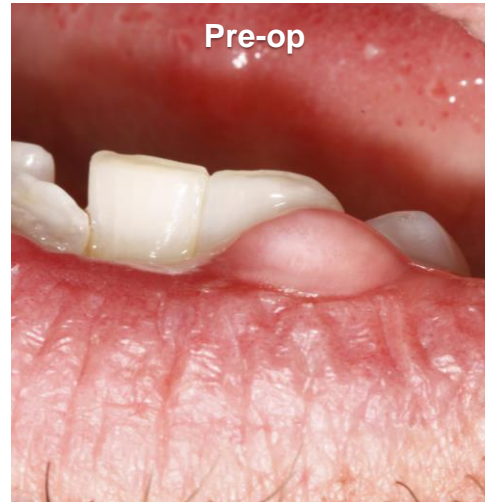


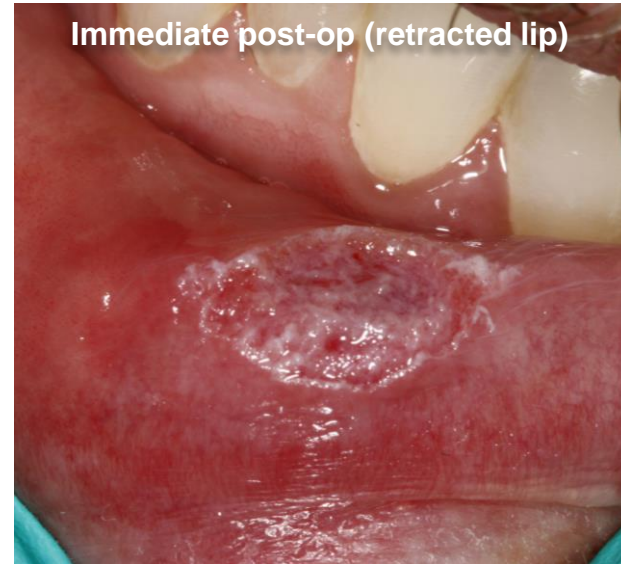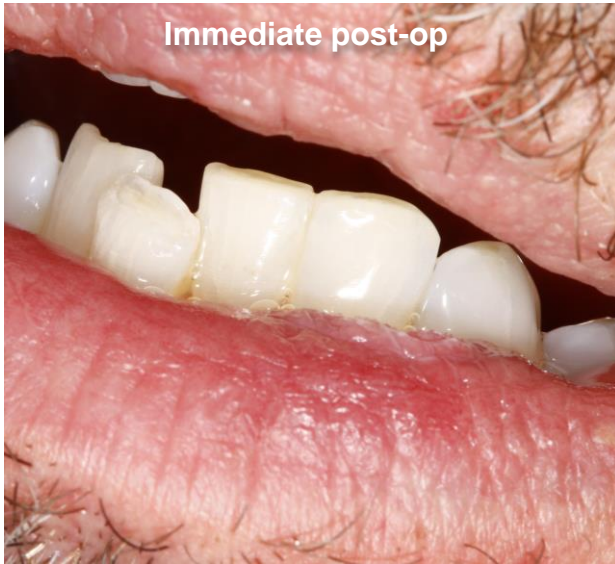**Fibroma removal
performed by
Joshua Weintraub,
DDS**

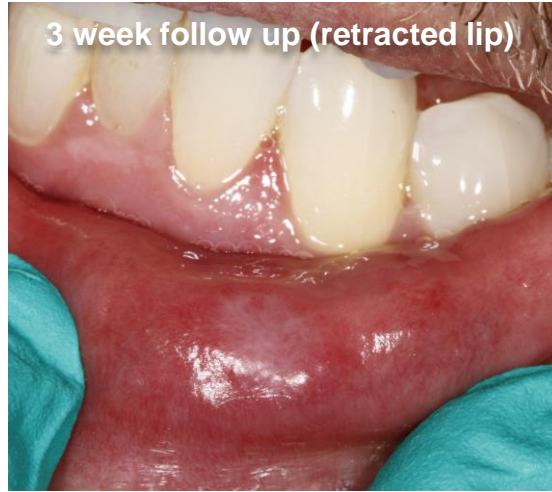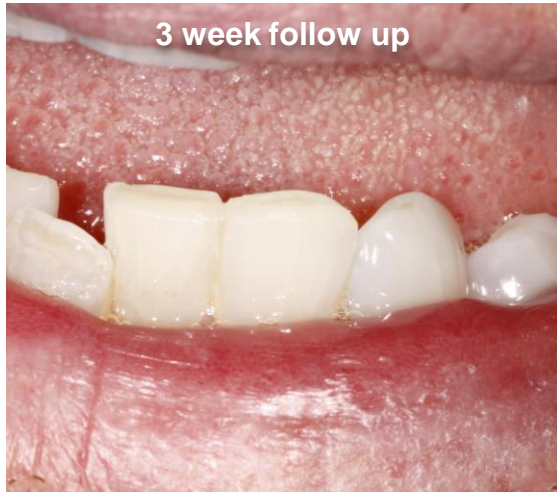*This case demonstrates
the ease and speed with
which soft tissue
procedures can be
performed injection and
blood-free along with an
excellent post-operative
experience.*



Case Summary: A 52-year-old male patient presented to the practice with a large oral lesion on his lower lip that bothered him esthetically. He was referred to the practice by a prosthodontist who preferred the dentist's Solea treatment to the traditional oral surgery. The patient complained about biting the lesion and about it being visible when he smiled. The oral evaluation revealed that this fibroma-like lesion measured 7mm x 5mm x 5mm. His anterior crowding was causing trauma to the lip resulting in a fibroma. The patient agreed to excisional biopsy of the lesion.



Technique Used: To start, only compound topical anesthetic was applied. Then, the dentist used tissue forceps to elevate the lesion and excised it by cutting laterally with Solea at the level of the surrounding tissue, essentially “severing” the lesion from the lip. He used the 0.5 mm spot size with 10% mist and cutting speed between 30-50%. After excision, the area was briefly lasered with the 1.25 mm spot size, 10% mist and 20-30% cutting speed to smooth peripheral borders of the surgical site. This left the flat surgical site without the need for sutures. There was no bleeding. Incisors were recontoured slightly for better esthetics and to avoid future trauma to the lip. The total procedure time was approximately 3 minutes. The specimen was preserved in formalin and sent to pathology. The pathology report confirmed diagnosis of fibroma.



Results: By using Solea, the dentist was able to finish this procedure in much less time than with traditional instruments. Moreover, he achieved a better clinical outcome and improved the overall patient experience. The patient was excited to eliminate the unsightly lesion. He was able to leave the office and go back to work right away. His post-operative healing was rapid and comfortable.

Solea Advantage:

- There was no bleeding, which made this procedure simple for the dentist to perform and for the patient to undergo.
- The procedure time was approximately 3 minutes compared to what would have been at least 30 minutes with other techniques.
- Patient received a much better experience that includes not being injected with anesthesia and no need for sutures.
- Minimally invasive approach resulted in minimal post-operative discomfort and fast healing.